

Reconstructive surgical correction of ulnar nerve paralytic claw fingers in Hansen's disease patients by Lasso procedure

Isaac Olusayo Amole, Stephen Adesope Adesina, Adewumi Ojeniyi Durodola, Adenike Adeniran, Olufemi Timothy Awotunde, Samuel Uwale Eyesan

ABSTRACT

Introduction: Hansen's disease is a chronic infectious granulomatous disease caused by *Mycobacterium leprae* and the organisms affect mainly peripheral nerves and skin. The deformities seen in Hansen's disease may result from the disease process or paralysis of some muscles due to damage to peripheral nerve trunk or injuries/infection to hands or feet. Reconstructive surgery for Hansen's disease patients is one of the ways of eliminating stigma associated with deformities and it also helps in restoring patient's ability to carry out some basic functions.

Case Series: Four cases of claw fingers resulting from ulnar nerve paralysis were considered in this study. Two of them dropped out of school because of the deformities. All of the patients considered in this study had mobile claw fingers and three of them had associated contracture. The contractures were corrected with serial manipulation and casting with Plaster of Paris before commencement of preoperative physiotherapy. They were operated using

Zancolli Lasso procedure under local anesthetics as regional block and had an uneventful postoperative period. All of them had satisfactory correction of their deformities.

Conclusion: Reconstructive surgery for Hansen's disease patients is one of the ways of eliminating stigma associated with deformities and it also helps in restoring patient's ability to carry out some basic functions. The selection criteria for optimal outcome in reconstructive surgery for Hansen's disease patients must be strictly followed in order to have a good outcome.

Keywords: Clawing, Lasso procedure, Reconstruction, Ulnar nerve

How to cite this article

Amole IO, Adesina SA, Durodola AO, Adeniran A, Awotunde OT, Eyesan SU. Reconstructive surgical correction of ulnar nerve paralytic claw fingers in Hansen's disease patients by Lasso procedure. J Case Rep Images Med 2016;2:31–35.

Article ID: 100015Z09IA2016

doi:10.5348/Z09-2016-15-CS-8

Isaac Olusayo Amole¹, Stephen Adesope Adesina¹, Adewumi Ojeniyi Durodola¹, Adenike Adeniran², Olufemi Timothy Awotunde², Samuel Uwale Eyesan³

Affiliations: ¹FWACP(FM), Consultant, Department of Family Medicine, Bowen University Teaching Hospital, Ogbomoso, Oyo State, Nigeria; ²FMCGP, Consultant, Department of Family Medicine, Bowen University Teaching Hospital, Ogbomoso, Oyo State, Nigeria; ³FMCS(Ortho), Consultant, Department of Surgery, Bowen University Teaching Hospital, Ogbomoso, Oyo State, Nigeria.

Corresponding Author: Isaac Olusayo Amole, Bowen University Teaching Hospital, P.O. Box 15, Ogbomoso, Oyo State, Nigeria, 009234; Email: amoleio@yahoo.com

Received: 11 December 2015

Accepted: 16 March 2016

Published: 16 April 2016

INTRODUCTION

Hansen's disease is a chronic infectious granulomatous disease caused by *Mycobacterium leprae* and the organism affects mainly peripheral nerves and skin [1]. Hansen's disease is one of the foremost causes of deformities and crippling. The deformities seen in Hansen's disease may result from the disease process (e.g., loss of eyebrows, other facial deformities), or paralysis of some muscles due to damage to peripheral nerve trunk

(e.g., claw-hand, foot-drop, lagophthalmos), or injuries and infection to hands or feet (e.g., scar contractures of fingers, mutilation of hands and feet, corneal ulceration) [1].

The present multidrug therapy (MDT) regimen used for Hansen's disease was introduced in the early 1980's and since the introduction of this regimen the prevalence of Hansen's disease has dropped significantly [2]. However, the deformities and disabilities resulting from this disease may be responsible for the stigmatization, rejection and other personal and social problems faced by these patients in the society [3]. One of the ways in which stigmatization and rejection in the society can be prevented is by correcting deformities resulting from Hansen's disease.

There was no center in Nigeria where Hansen's disease patients could have their deformities corrected. Damien Foundation Belgium thought it fit to establish such a center in Nigeria hence the decision to sponsor training of a doctor and a physiotherapist in reconstructive surgery for Hansen's disease. The training took place in India in 2014. On completion of the training, the first and only reconstructive surgery center for Hansen's disease patients in Nigeria was established in collaboration with Bowen University Teaching Hospital, Ogbomoso in February 2015. This paper presents, the first four cases of correction of claw hand resulting from ulnar nerve paralysis carried out at the center.

CASE SERIES

Zancolli Lasso Procedure

The surgeries were done under Brachial Block with a tourniquet. The flexor digitorum superficialis (sublimis) tendon of the middle finger (S3) was identified through an incision over the middle crease of the middle finger and both its slips were detached from their insertion at the base of the middle phalanx. The tendon was pulled out and the chiasma divided. This tendon was then withdrawn through a mid-palmar incision near the wrist. Through another incision over the distal crease of the palm, all flexor tendons and their sheath from the second to the fifth fingers were identified. A2 pulleys of each of these tendon sheaths were identified. The S3 tendon at the proximal palmar incision was then split into four slips and were routed through the lumbrical canal of individual fingers and brought out at the distal palmar crease. Each of these slips were then looped under each A2 pulley of individual flexor sheath and stitched upon itself with adequate tension so that the hand assumes a normal hand at rest. After ensuring hemostasis, all incisions were closed and the hand put in a Plaster of Paris (POP) cast.

Case 1

A 20-year-old boy presented with claw right hand of five years duration. He was diagnosed to have Hansen's

disease about 10 years ago and was treated with MDT for a year. He dropped out of primary school because of the disease and the associated deformities. There was no history of the disease in the family. On examination, he was found to have a claw hand resulting from ulnar nerve paralysis. The metacarpophalangeal, proximal and distal interphalangeal joints were mobile but he had contracture of the four fingers. Serial manipulation and casting with POP was done until the contractures were overcome. Preoperative physiotherapy was done to strengthen the flexor digitorum superficialis muscle of the middle finger. He was operated using the Zancolli Lasso procedure. The POP and the operation site sutures were removed after three weeks and he had postoperative physiotherapy for three weeks (Figure 1).

Case 2

A 26-year-old tailor presented with claw right hand of six years duration. He was diagnosed to have Hansen's disease about six years ago and was treated with MDT for a year. He dropped out of secondary school because of the disease and the associated deformities. His mother had the same disease and also developed complications from the disease. He is presently learning tailoring but the hand deformity prevented him from having a smooth sewing. On examination, he was found to have a claw hand resulting from ulnar nerve paralysis. The metacarpophalangeal, proximal and distal interphalangeal joints were mobile but he had contracture of the ring and little fingers. Serial manipulation and casting with POP was done until the contractures were overcome. Preoperative physiotherapy was done to strengthen the flexor digitorum superficialis muscle of the middle finger. He was operated using the same technique. The POP and the operative site sutures were removed after three weeks and he had postoperative physiotherapy for three weeks (Figure 2).

Case 3

A 39-year-old electrician presented with claw right hand of 15 years duration. He was diagnosed to have Hansen's disease about 17 years ago and was treated with MDT for a year. He graduated from a polytechnic in Nigeria with an Ordinary National Diploma (OND) degree. He is married and there was no history of the disease in the family. On examination, he was found to have a claw hand resulting from ulnar nerve paralysis. The metacarpophalangeal, proximal and distal interphalangeal joints were mobile but he had contracture of the ring and little fingers. Serial manipulation and casting with POP was done until the contractures were overcome. Preoperative physiotherapy was done to strengthen the flexor digitorum superficialis muscle of the middle finger. He was operated using the same technique. The POP and the operative site sutures were removed after three weeks and he had postoperative physiotherapy for three weeks (Figure 3).

Case 4

A 60-year-old security man presented with claw right hand of 27 years duration. He was diagnosed to have Hansen’s disease about 30 years ago and was treated with MDT for a year. There was no history of the disease in the family. On examination, he was found to have a claw hand resulting from ulnar nerve paralysis. The metacarpophalangeal, proximal and distal interphalangeal joints were mobile. Preoperative physiotherapy was done to strengthen the flexor digitorum superficialis muscle of the middle finger. He was operated using the same technique. The POP and the operation site sutures were removed after three weeks and he had post-operative physiotherapy for three weeks (Figure 4).



Figure 4: Preoperative and postoperative pictures of Case 4.

DISCUSSION

Deformities in Hansen’s disease are the consequence of impairments of nerve function. The nerve trunks of the ulnar nerve and median nerve are frequently affected by leprosy, resulting in paralysis of these nerves. Thus, many leprosy patients develop ulnar nerve paralysis alone, or combined paralysis of ulnar and median nerves. The paralysis of ulnar nerve results in ulnar or partial claw hand, involving the fingers mainly, while the paralysis of ulnar and median nerves gives rise to total claw-hand involving the thumb as well as the fingers [4]. All our four cases had partial claw hand following ulnar nerve paralysis.

Clawing is defined as hyperextension at metacarpophalangeal joint and flexion of interphalangeal joint. Clawing of fingers not only weakens the hand, but also leads to instability, non-coordination, imbalance and synergism [5]. The overall effect is a poor grip due to unstable metacarpophalangeal joint, poor grasp due to inadequate opening of the hand and poor pinch due to unstable metacarpophalangeal joint of the index finger and thumb. The normal opening and closing pattern of fingers are lost. In normal hand the metacarpophalangeal joint flexion initiated total finger flexion and all joints close nearly simultaneously [6].

The deformities arising from Hansen’s disease stigmatize the affected persons. Furthermore, because they involve the hands, these persons also experience certain disabilities in the use of their hands. Stigma is a serious issue with Hansen’s disease. Many affected young persons have dropped out of school because of deformities as seen in the first two cases. Many more have lost their jobs because of disabilities and stigma following the deformities. Reconstructive surgery for Hansen’s disease patients is one of the ways of eliminating stigma associated with deformities and it also helps in restoring patient’s ability to carry out some basic functions.

Claw-finger and Z-thumb deformities are common deformities following ulnar paralysis in Hansen’s disease patients. Correction of claw hands in these patients is achieved by transferring a motor tendon, such as the tendon of flexor digitorum superficialis (FDS), palmaris longus, extensor carpi radialis longus (ECRL) or extensor



Figure 1: Preoperative and postoperative pictures of Case 1.




Figure 2: Preoperative and postoperative pictures of Case 2.

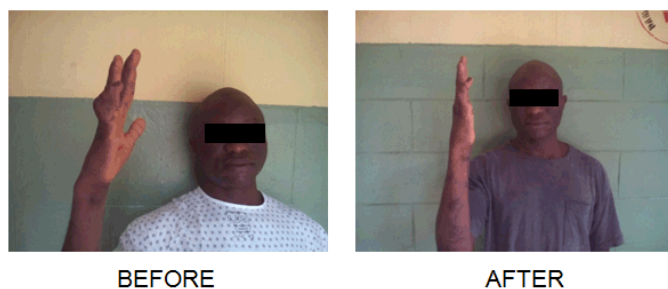

Figure 3: Preoperative and postoperative pictures of Case 3.

indices to any one of four insertion sites in the fingers [7]. These insertion sites are the lateral band of the dorsal extensor expansion [8, 9], the proximal phalanx, [10] the proximal annular pulleys of the flexor sheath [11] and the interossei tendons [12].

The aims of the surgical procedures are to prevent hyperextension at the metacarpophalangeal joint and to initiate flexion of the proximal phalanx as in normal hands and also to reinforce the extensor power to extend the interphalangeal joints as in dynamic procedures. Most of the procedures currently used for correction of clawing of fingers need good and extensive postoperative re-education and training and also they require operative skill and more time.

Zancolli Lasso procedure for correction of claw hand has been used by many because it is simple to perform with minimal complications; re-education of transferred tendon is easy and gives better results. Zancolli had described two types of Lasso procedure to correct clawing of the fingers. In direct Lasso all FDS tendons of the fingers or one flexor digitorum superficialis tendon, split into four slips are used. In indirect Lasso a different muscle like Palmaris Longus, Extensor Carpi radialis longus or brachioradialis is used by extending it using a free graft. The direct lasso procedure was used in all our four cases and the procedure was described under surgical technique.

In order to have a good outcome the patients must be properly selected. The following are the selection criteria for optimal outcome in reconstructive surgery for Hansen's disease patients: The ideal age group is between 15 and 45 years (though one of our patients was 60-year-old and was included because he was able to master preoperative exercises), the duration of paralysis should be at least one year, the patients should have completed MDT treatment if paucibacillary or should have been on treatment for at least six months if multibacillary; the patients should not have had a reaction within the last six months; patients on steroid treatment should wait until six months after completing the course of steroid therapy; patients should be free of all kinds of infectious dermatological conditions. Female patients should not be pregnant at the time of the surgery and if she delivered it should be six months post-delivery and finally, significant contracture must be corrected with serial casting with POP before commencement of preoperative physiotherapy.

The aims of preoperative physiotherapy are to keep the skin soft without crack and ulcer, to keep the joint mobile and to increase the strength of the muscle intended for the transfer. The preoperative physiotherapy should be for at least 7–10 days before the surgery and the physiotherapy comprises exercises, oil massage, wax baths, hydrotherapy and splinting. The postoperative physiotherapy usually lasts a period of four weeks during which patients actually learn to use the transferred tendon effectively. They also learn how to protect the new tendon insertion during healing and regain pre-operative range of movements and strengths [13].

CONCLUSION

Reconstructive surgery for Hansen's disease patients is one of the ways of eliminating stigma associated with deformities and it also helps in restoring patient's ability to carry out some basic functions hence reducing their social dependence. The selection criteria for optimal outcome in reconstructive surgery for Hansen's disease patients must be strictly followed in order to have a good outcome.

Acknowledgements

We would like to appreciate Damien Foundation Belgium for sponsoring the training of the doctor and the physiotherapist and for the establishment of the Reconstructive Center. We also appreciate Mrs. Areegbe Tinuola Iyabo for providing physiotherapy service.

Author Contributions

Isaac Olusayo Amole – Substantial contributions to conception and design, Acquisition of data, Analysis and interpretation of data, Drafting the article, Revising it critically for important intellectual content, Final approval of the version to be published

Stephen Adesope Adesina – Substantial contributions to conception and design, Acquisition of data, Analysis and interpretation of data, Drafting the article, Revising it critically for important intellectual content, Final approval of the version to be published

Adewumi Ojeniyi Durodola – Substantial contributions to conception and design, Drafting the article, Revising it critically for important intellectual content, Final approval of the version to be published

Adenike Adeniran – Substantial contributions to conception and design, Drafting the article, Critical revision of the article, Final approval of the version to be published

Olufemi Timothy Awotunde – Substantial contributions to conception and design, Drafting the article, Revising it critically for important intellectual content, Final approval of the version to be published

Samuel Uwale Eyesan – Substantial contributions to conception and design, Drafting the article, Revising it critically for important intellectual content, Final approval of the version to be published

Guarantor

The corresponding author is the guarantor of submission.

Conflict of Interest

Authors declare no conflict of interest.

Copyright

© 2016 Isaac Olusayo Amole et al. This article is distributed under the terms of Creative Commons Attribution License which permits unrestricted use,

distribution and reproduction in any medium provided the original author(s) and original publisher are properly credited. Please see the copyright policy on the journal website for more information.

REFERENCES

1. Chavan LB, Patel P. Epidemiology of disability in incident leprosy patients at supervisory urban leprosy unit of Nagpur city. *National Journal of Community Medicine* 2011;2(1):119–22.
2. Garg BS, Deshmukh PR. Progress Towards leprosy elimination in Maharashtra state and Reflection from Leprosy Elimination Monitoring, 2003. *J Mahatma Gandhi Inst Med Sci* 2004;9(1):5–9.
3. Farooq RS, Ghulam MP, Parvez A, Nuzhat SB, Javeed HY. Deformity and disability index in patients of leprosy in Larkana region. *Journal of Pakistan Association of Dermatologists* 2008;18:29–32.
4. Cochrane RG. *Practical Textbook of Leprosy*. London: Oxford University Press; 1947. p. 52.
5. Palande DD. Correction of paralytic claw finger in leprosy by capsulorrhaphy and pulley advancement. *J Bone Joint Surg Am* 1976 Jan;58(1):59–66.
6. Deepak N, Galfat DR, Raghvendra S. Reconstructive surgical correction of paralytic claw fingers in leprosy by lasso procedure. *International Journal of Orthopaedics Traumatology and Surgical Sciences* 2015;1(1):9–12.
7. Fritschi E, Hamilton J, James JH. Repair of the dorsal apparatus of the finger. *Hand* 1976 Feb;8(1):22–31.
8. Brand PW. The reconstruction of the hand in leprosy. *Ann R Coll Surg Engl* 1952 Dec;11(6):350–61.
9. Brand PW. Deformity in leprosy. In: Cochrane RG, Davey TF eds. *Leprosy in theory and practice*. Bristol: John Wright & Sons Ltd; 1964. p. 447–67.
10. Burkhalter WE. Early tendon transfer in upper extremity peripheral nerve injury. *Clin Orthop Relat Res* 1974 Oct;(104):68–79.
11. Anderson GA. Analysis of paralytic claw finger correction using flexor motors intodifferent insertion sites: thesis. University of Liverpool, 1988.
12. Anderson GA. Ulnar nerve palsy. In: Green DP, Hotchkiss RN, Pederson WC, Wolfe SW eds. *Green's operative hand surgery*. 5ed. London: Elsevier; 2005. p. 1167–93.
13. Zancolli EA. *Structural and Dynamic Bases of Hand Surgery*, 2ed. Philadelphia: JB Lippincott; 1979.

Access full text article on
other devices



Access PDF of article on
other devices

